



THE EFFICACY OF FRACTIONAL PICOSECOND 1064NM ND-YAG LASER IN THE TREATMENT OF ATROPHIC ACNE SCARS

Nguyen Ngoc Diep^{1,2}, Nguyen The Vy², Nguyen Thi Lan², Le Hai Yen², Pham Thi Lan^{1,3}

SUMMARY

Objectives: To evaluate the efficacy of fractional picosecond 1064nm Nd-YAG laser in the treatment of acne scar.

Methods: This is an uncontrolled prospective study. 32 patients with atrophic acne scars were enrolled into study to receive 3 sessions of fractional picosecond 1064nm Nd-YAG laser treatment at 4-week intervals. The laser settings were 0.8J/cm² in fluence, 8-mm spot size, 5% coverage and 5Hz in repetition rate. The primary outcome was the change in Goodman and Baron's quantitative and qualitative grading scale between baseline and 3 months after the last treatment.

Results: Goodman and Baron scale significantly decreased after the treatments with 12,1 (\pm 5.51) points in mean reduction ($p < 0.001$). There was a significant improvement in scar color, in which the red scar color reduced from 24.5% to 3.8% ($p < 0.001$). There were 73.1% of patients improved a scar degree. The number of scars (including icepick, rolling, and boxcar scars) also significantly decreased from after treatment ($p < 0.001$). No patient developed postinflammatory hyperpigmentation.

Conclusion: Fractional picosecond 1064nm Nd-YAG laser is an effective option for treating atrophic acne scars.

Keywords: *Atrophic acne scars, Nd-YAG laser, fractional picosecond.*

1. INTRODUCTION

The atrophic scar is a common complication of acne, initiated by infra-fundibular inflammation and around inflammatory folliculitis [1]. Atrophic scars had a proportion of about 80 - 90% in the cases of acne scar [2]. Currently, there are many modalities for atrophic scar treatments including subcision, micro-needling combined Cross TCA, fractional RF, fractional/nonablative laser CO₂, ablative resurfacing lasers such as laser CO₂ or Er-YAG, and punch excision [3], [4], [5], [6]. Fractional

RF is considered the most effective method but requires quite long downtime and have high risk of side effects for darker skin like Asian skin [7]. Therefore, it required the experience and caution to perform the procedure in atrophic scar treatment. Nowadays, a new therapeutic approach in atrophic scar treatment with Fractional Picosecond 1064nm Nd-YAG Laser has become popular because it has demonstrated clinical efficacy in European for improving acne scars, low risk of side effects, and short downtime [8].

The aim of this study was to evaluate the efficacy of fractional picosecond 1064nm Nd-YAG laser in the treatment of acne scar in Vietnamese patients.

1: Hanoi Medical University, Hanoi, Vietnam

2: Hanoi Dermatology Hospital, Hanoi, Vietnam

3: National Hospital of Dermatology and Venereology

2. MATERIAL AND METHODS

2.1. Study populations

The inclusion criteria includes patients with atrophic acne scars who have age over 15 years old. The inclusion criteria includes isotretinoin use within the previous six months, active cutaneous bacterial or viral infection in the area to be treated, active acne, history of keloid formation or hypertrophic scarring, ongoing ultraviolet exposure, prior radiation therapy to treatment area, active collagen vascular diseases, chronic diseases such as diabetes and HIV/AIDS, skin cancer, actinic keratosis and photochromic skin disease. By the end of the enrollment period, 32 patients were recruited into the study.

2.2. Study design

The study was conducted between July 2021 and July 2022 at Hanoi Dermatology Hospital. This is a prospective study of a pre-post treatment comparative clinical trial.

2.3. Study intervention

All participants were provided detailed information about the study by the researcher and completed the written informed consent.

The patient was treated using a fractional picosecond 1064nm Nd-YAG laser with fractionated

microlens array handpiece. The laser settings include 0.8J/cm² in fluence, 8-mm spot size, 5% coverage and 5Hz in repetition rate. Treated areas were applied antibiotic gel (Tyrosur® gel 5g). Each patient received 3 treatments at 4-week intervals. Topical anesthesia was not used. Endpoints were immediate moderate erythema and mild oozing of bloody serous exudates, a sign of epidermal ablation. Therefore, we safely used high fluences with a good margin of safety. After treatment, patients were required to use topical antibiotic (Tyrosur gel 5g) two 2 times a day for 7 - 10 days and use topical sunscreen after scabbing (Avene® Sunscreen High Protection SPF 50+) every 2 - 3 hours in daytime.

2.4. Outcome and safety assessments

The efficacy was evaluated by the same dermatologist. Demographic characteristics were obtained at baseline. Goodman and Baron's quantitative and qualitative grading scale was used to measure the atrophic scars acne status (Table 1) [9]. The primary outcome was the change in Goodman and Baron scale between baseline and 1, 2, 3 and 4 months after baseline. The secondary outcomes include the change in number of each type of atrophic scar acne (including icepick, rolling, and boxcar scars) and change in scar color.

Table 1. Goodman and Baron's quantitative grading scale

(Grade) Type	Number of lesions: 1 (1 - 10)	Number of lesions: 2 (11 - 20)	Number of lesions: 3 (21 - 30)
A Milder scarring (1 point each)	1 point	2 points	3 points
B Moderate scarring (2 points each)	2 points	4 points	6 points
C Severe scarring (3 points each)	3 points	6 points	9 points
D Hyperplastic (popular)	2 points	4 points	6 points
E Hyperplastic	< 5 cm ² Area	5 - 20 cm ² Area	> 20 cm ² Area
Total	6 points	12 points	18 points



2.5. Statistical analysis

Statistical methods were calculated using IBM SPSS Statistics for Windows, version 20 (IBM Crop). All continuous data were presented as mean; paired t-test was used to compare between group and same group means, respectively. All categorical data were reported in percentage. The chi-squared test and Fisher's exact test were used for the comparison. P-values less than 0.05 were considered significant.

2.6. Ethical approval

This study was approved by the Ethics Committee of Hanoi Medical University and Hanoi Dermatology Hospital. The study was explained to all respondents willing to participate in it and all participants granted their consent before participating in the study. All participants signed the informed consent. All participants had the right to withdraw from the study at any time.

3. RESULTS

Thirty two patients were enrolled into this study. The intervention were performed in all patients with no drop out of participants.

Baseline demographic and clinical characteristics of the patients are showed in Table 2. Patients in the study are mainly female (59.4%) with the main age group from 20 to 39 years old. The scars are mainly grade 4 scars (65.5%), boxcar (43.9%), in the cheek area (37.5%) and skin-color (46.9%).

Goodman and Baron's quantitative scale scores significantly decreased right after 1 month while Goodman and Baron's quantitative scale scores significantly decreased after 2 months and continued to decrease in the following treatments (Table 3). Number of every scar types significantly decreased after only 1 month and continued to decrease in the following treatments (Table 3).

After 4 months, number of red and dark color significantly decreased with 84.4% of scar returning to skin-color (Table 4).

Side effects of treatment are showed in Table 5 in which no patient developed PIH or scar.

Table 2. The demographic and clinical characteristics of patients at baseline (n = 32)

Characteristics	n	%
Sex		
Male	13	40.6
Female	19	59.4
Age (years)		
< 19	5	15.6
20 - 39	26	81.2
40 - 59	1	3.1
Scar grading		
Grade 2	2	6.2
Grade 3	9	28.1
Grade 4	21	65.6
Predominant scar type		
Icepick	7	21.8
Rolling	11	34.3
Boxcar	14	43.9
Position of scar		
Chin	2	6.2
Jaw	1	3.1
Cheek	12	37.5
Nose	3	9.4
Temple	6	18.8
Forehead	8	25.0
Color of scar		
Normal	15	46.9
Red	10	31.2
Dark	7	21.9

Table 3. The change in Goodman and Baron's quantitative scale and number of scar after treatment (n = 32)

Outcomes	Baseline	After 1 month	After 2 months	After 3 months	After 4 months
Goodman and Baron's quantitative scale					
Mean (SD)	31.6 (9.81)	30.4 (9.87) *	27.7 (9.93) *	23.0 (9.73) *	19.5 (9.58) *
Goodman and Baron's qualitative scale					
Mean (SD)	3.59 (0.615)	3.59 (0.615)	3.28 (0.634) *	2.81 (0.738) *	2.41 (0.712) *
Number of icepick scars					
Mean (SD)	19.6 (9.10)	18.7 (8.91) *	17.3 (8.68) *	11.7 (7.14) *	9.25 (6.29) *
Number of rolling scars					
Mean (SD)	19.5 (7.94)	18.7 (8.01) *	17.7 (8.10) *	13.5 (7.20) *	11.3 (6.67) *
Number of boxcar scars					
Mean (SD)	23.0 (8.23)	22.2 (8.04) *	20.9 (7.91) *	16.8 (7.52) *	14.7 (7.06) *

* *p*-value < 0.001

Table 4. The change in scar color after treatment (n = 32)

Time		Color of scars			p-value
		Normal	Red	Dark	
Baseline	n	16	10	8	-
	%	50.0	31.3	25.0	
After 1 month	n	15	11	8	> 0.05
	%	46.9	34.4	25.0	
After 2 months	n	15	11	7	< 0.05
	%	46.9	34.4	21.9	
After 3 months	n	18	10	4	< 0.05
	%	56.3	31.3%	12.5	
After 4 months	n	27	5	0	< 0.001
	%	84.4	15.6	0.0	



Table 5. Side effects of treatment after 4 months

Adverse events	%
Pain	100
Erythema	100
Edema	100
Scale	0
Pruritus	0
Postinflammatory hyperpigmentation	0
Scar	0
Other	0

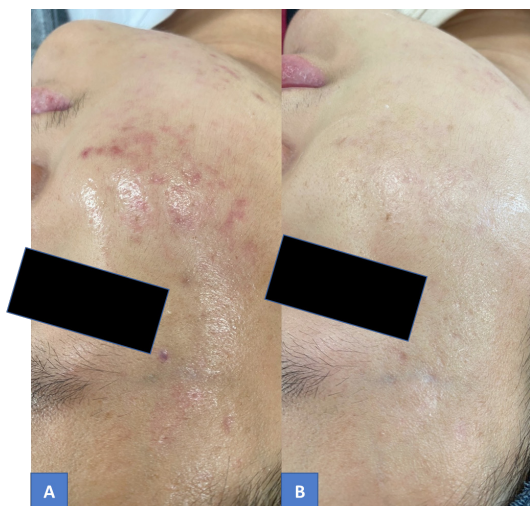

Figure 1. Before (A) and 3 months after treatments (B)

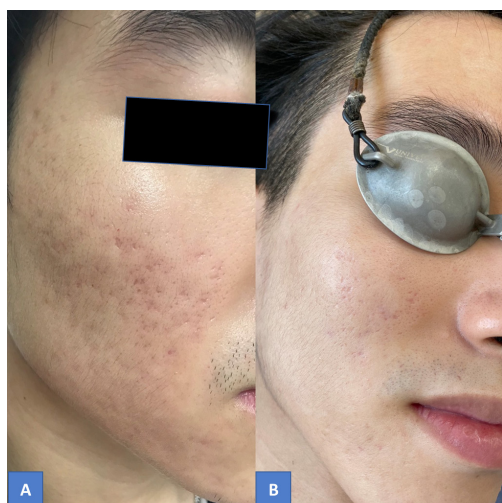

Figure 2. Before (A) and 3 months after treatments (B)

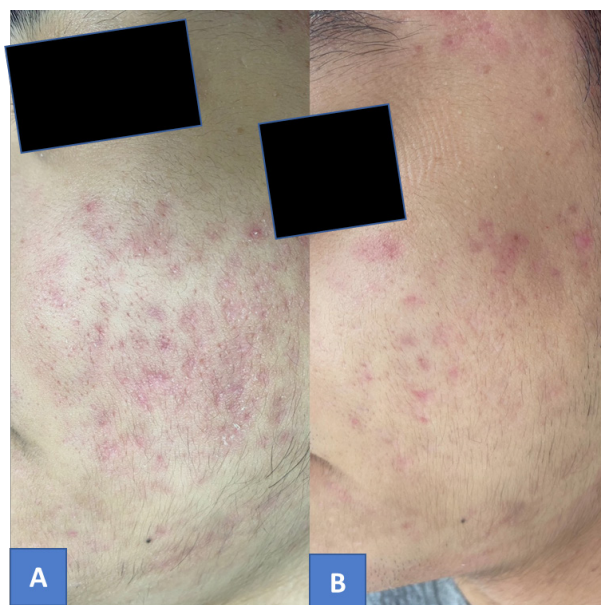


Figure 3. Before (A) and 3 months after treatments (B)

4. DISCUSSION

The main age group in our study is consistent with the age of acne and similar to other studies [10]. Females made up the majority of our study and this is similar to other studies like Chuah's study on 100 patients that females accounted for 57% and Hayashi's study with 70.4% [10] [11]. The modest difference in the ratio of men to women in our study shows that in today's modern society, men and women have similar aesthetic needs.

Scar severity in this study was assessed by Goodman and Baron scale including quantitative scale and quantitative scale. Baseline scars have mainly moderate and severe degree. Quantitative scale scores statistically significantly decreased right after 1 month while quantitative scale scores statistically significantly decreased after 2 months and continued to decrease in the following treatments. In the study of acne scar treatment by ablative fractional radiofrequency (RF) by Nguyen Thi Kim Cuc, the degree of scar improvement was

evaluated according to 4 levels, the improvement of the scar index according to the Goodman and Baron scale was almost negligible after the first session [12]. The proportion of patients with grade 4 scars decreased from 71.2% before the treatment to 38.5% after 3 months, then 25% 3 months after the treatment (reduced by 2.8 times). The number of patients with grade 2 scars increased from 0% before the treatment to 28.8% 3 months after the treatment [12]. According to Goodman and Baron, there was a difference in scar scales between our study and the study by Nguyen Thi Kim Cuc because the patients chosen in our study had more severe severity than in the study by Kim Cuc [12]. However, the scar improvement rate in the two studies was similar.

Our study also showed a good improvement in the number of scars. Number of every scar types significantly decreased after only 1 month and continued to decrease in the following treatments. This is a very positive result because the majority of scars in the study were grade 4 scars.

Regarding the colour of scars, our study showed that 25% were dark scars and 31.2% were red scars before the treatment. There was no change in scar colour after the first sessions. However, after the second session, the patients' scar colour improved. After that, number of red and dark color significantly decreased with higher skin-color tuning after each treatment. After the fourth session, the percentage of patients with dark scars

was 0%, and the rate of the red scar significantly decreased from 31.2% to 15.6% (before and after the treatment). The percentage of normal skin after the end of this treatment is higher than the study of Nguyen Thi Kim Cuc's study [12].

In this study, we used fractional picosecond 1064nm Nd-YAG laser with low-fluence and big spot size so it was quite safety method. No patient developed post inflammatory hyperpigmentation or hypertrophic scar. Common side effects after laser like pain, edema and erythema were present in all patients but quickly disappeared.

There were some limitations in our study. Firstly, the sample size was quite small. Secondly, we did not find the factor which affected the efficacy of the treatment to point out how to implement the Fractional Picosecond 1064nm Nd-YAG Laser treatment to different patients' characteristics. So, the next study should consider the implementation of the Fractional Picosecond 1064nm Nd-YAG Laser treatment as an outcome to reduce this limitation.

5. CONCLUSION

Fractional picosecond 1064nm Nd-YAG laser is an effective option for treating atrophic acne scars, help to reduce Goodman and Baron's quantitative and qualitative grading scale, reduce number of scars and turn scar into skin-color. This is also a quite safety therapeutic when compared with other therapeutics with no case of post-inflammatory hyperpigmentation recorded.

REFERENCES

1. Shamban A.T. and Narurkar V.A. (2009). Multimodal treatment of acne, acne scars and pigmentation. *Dermatol Clin*, 27(4), 459-471, vi.
2. Bencini P.L., Tournalaki A., Galimberti M. and al (2012). Nonablative fractional photothermolysis for acne scars: clinical and in vivo microscopic documentation of treatment efficacy. *Dermatol Ther*, 25(5), 463-467.
3. Alster T.S., Tanzi E.L., and Lazarus M. (2007). The use of fractional laser photothermolysis for the treatment of atrophic scars. *Dermatol Surg*, 33(3), 295-299.



4. Hwang Y.J., Lee Y.N., Lee Y.W. and al. (2013). Treatment of Acne Scars and Wrinkles in Asian Patients Using Carbon-Dioxide Fractional Laser Resurfacing: Its Effects on Skin Biophysical Profiles. *Ann Dermatol*, 25(4), 445-453.
5. Manuskiatti W., Triwongwaranat D., Varothai S. and al. (2010). Efficacy and safety of a carbon-dioxide ablative fractional resurfacing device for treatment of atrophic acne scars in Asians. *J Am Acad Dermatol*, 63(2), 274-283.
6. Layton A., Dréno B., Finlay A.Y. and al. (2016). New Patient-Oriented Tools for Assessing Atrophic Acne Scarring. *Dermatol Ther (Heidelb)*, 6(2), 219-233.
7. Sirithanabadeekul P., Tantrapornpong P., Rattakul B. and al. (2021). Comparison of Fractional Picosecond 1064-nm Laser and Fractional Carbon Dioxide Laser for Treating Atrophic Acne Scars: A Randomized Split-Face Trial. *Dermatol Surg*, 47(2), e58-e65.
8. Tanghetti E.A. (2016). The histology of skin treated with a picosecond alexandrite laser and a fractional lens array. *Lasers Surg Med*, 48(7), 646-652.
9. Goodman G.J. và Baron J.A. (2006). Postacne scarring: a qualitative global scarring grading system. *Dermatol Surg*, 32(12), 1458-1466.
10. Chuah S.Y. và Goh C.L. (2015). The Impact of Post-Acne Scars on the Quality of Life Among Young Adults in Singapore. *J Cutan Aesthet Surg*, 8(3), 153-158.
11. Hayashi N., Miyachi Y., and Kawashima M. (2015). Prevalence of scars and “mini-scars”, and their impact on quality of life in Japanese patients with acne. *J Dermatol*, 42(7), 690-696.
12. Nguyen Thi Kim Cuc (2017), Clinical characteristics and effectiveness of treatment of acne scars with micro point radiofrequency (RF), Hanoi Medical University.