

# PATHOLOGICAL DIAGNOSIS IN MALIGNANT SKIN TUMORS

Nguyen Hoang An<sup>1,\*</sup>

## ABSTRACT

Skin cancer is a disease characterized by the uncontrolled growth of cells in the skin. There are two distinct types of skin cancer: nonmelanoma and melanoma. Melanoma is cancer of pigmented cells and is far more dangerous than nonmelanoma, which is the most common cancer in the United States. This article discusses the pathology of nonmelanoma skin cancers in depth, focusing on the two most common types of carcinoma. Squamous cell carcinoma develops from the surface of the epidermis and accounts for about one-fourth of nonmelanoma cases. Basal cell carcinoma is believed to derive from the basal layer of the epidermis or follicular epithelium, accounting for roughly three-fourths of cases. Immunohistochemistry is an extremely valuable adjunct to the standard morphologic diagnosis in diagnostic pathology. The diagnosis of epithelial tumors depends significantly on morphological features, but in rare cases, immunohistochemical stains are needed for a definitive diagnosis.

**Keywords:** *Carcinoma, skin tumors, immunohistochemistry.*

## 1. INTRODUCTION

Skin cancer is a disease characterized by the uncontrolled growth of cells in the skin. There are two distinct types of skin cancer: nonmelanoma and melanoma. Melanoma is cancer of pigmented cells and is far more dangerous than nonmelanoma. Skin cancer is one of the most common types of cancer and usually develops in areas of the skin exposed to the sun. The highest incidence is in outdoor workers, athletes, and sunbathers, and it is negatively correlated with

the amount of skin melanin; fair-skinned people are often the most sensitive. Skin cancers can also develop years after X-ray imaging or exposure to carcinogens.

The most common types of skin cancer are Basal cell carcinoma (about 80%), squamous cell carcinoma (about 16%), and Melanoma (about 4%). Less common types of skin cancer include Paget's disease of the breast or extramammary Paget's disease, Kaposi sarcoma, Merkel cell carcinoma, Adnexal tumor, Skin T-cell lymphoma, and Bowen's disease.

Initially, skin cancer is usually asymptomatic. If diagnosed and treated early, the prognosis is better than if diagnosed later. Although there are now many methods to help diagnose cancer, pathology is often the gold standard in diagnosing cancers, including skin cancer. It should make an

<sup>1</sup>Quy Hoa National Leprosy and Dermatology Hospital

\*Correspondence: [nguyenhoangandh@gmail.com](mailto:nguyenhoangandh@gmail.com)

Received 28 June 2023

Revised 26 September 2023

Accepted 29 November 2023

DOI: <https://doi.org/10.56320/tcdlhvn.42.139>



important contribution to early, precise diagnosis and treatment. Therefore, biopsies are indicated for any skin lesion, whether typical for cancer or atypical, and for those that are more extensive or persistent than usual.

## 2. PATHOLOGY DIAGNOSIS IN SKIN CANCER

### 2.1. Diagnosis of cancer by histopathology

The diagnosis of cancer by histopathology is the most important method, as it enables a definitive diagnosis, treatment planning, and disease prognosis. For each tumor, there are many different types of tissue. Histological classification is crucial for prognosis and treatment since each type of tissue exhibits a different degree of malignancy. The histopathological diagnosis of skin cancer is specific to each type of disease.

#### 2.1.1. Basal cell carcinoma<sup>1</sup>

##### 2.1.1.1. General histopathological characteristics of basal cell carcinoma

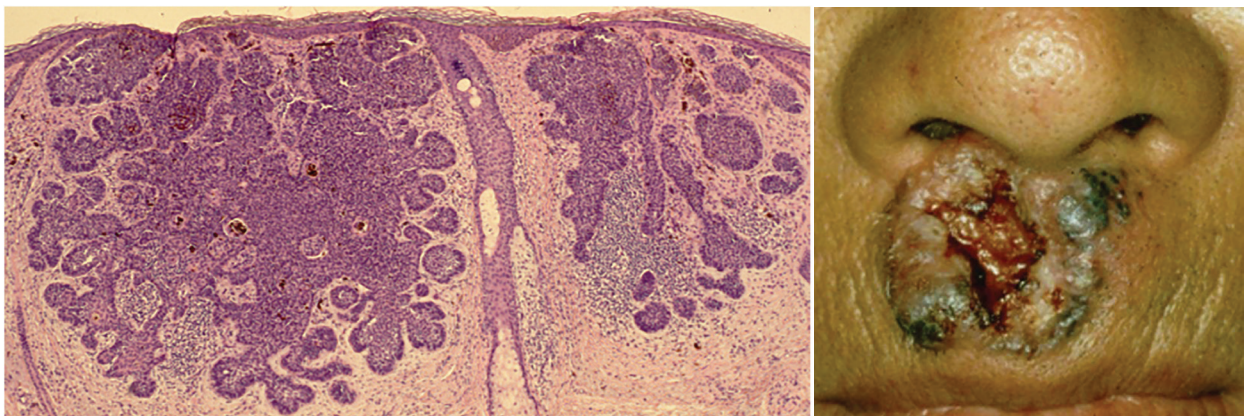
Basal cell carcinoma is a malignant carcinoma that originates from the basal cell layer of the epidermis or the hair follicle epithelium. Characteristic histopathological features on Hematoxylin & Eosin (HE) staining slides, used for diagnosing basal cell carcinoma, include cancer

cells with dark (alkaline) nuclei, a cylindrical shape, an increased nucleus-to-cytoplasm ratio, and loss of intercellular bridges. Clusters of cells at the periphery of the tumor are arranged in a palisade pattern. The most distinctive aspect of the tumor is its separation from the surrounding stroma to form a light or mucinous space, surrounded by clusters of cells in a palisade pattern. The cells inside the tumor exhibit considerable disorder. Most tumors initiate in the epidermis and then invade the dermis as solid nodules, cysts, or bands, resulting in various growth patterns. A common feature of large tumors is the presence of necrosis in the center. Several growth patterns of basal cell carcinoma have been described, serving as different prognostic factors for biological behavior.

##### 2.1.1.2. Histopathological classification of basal cell carcinoma

#### - Nodular type

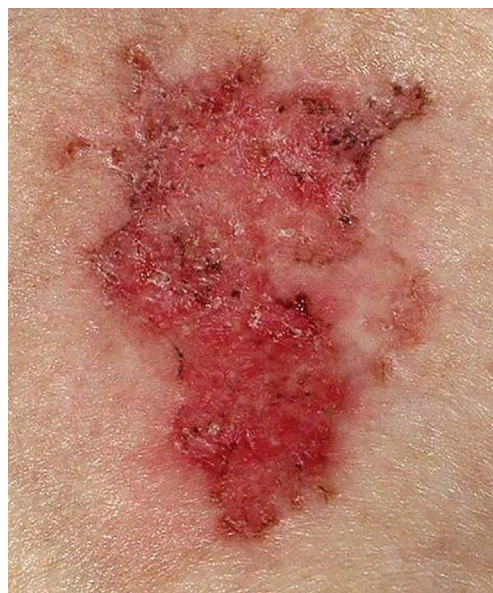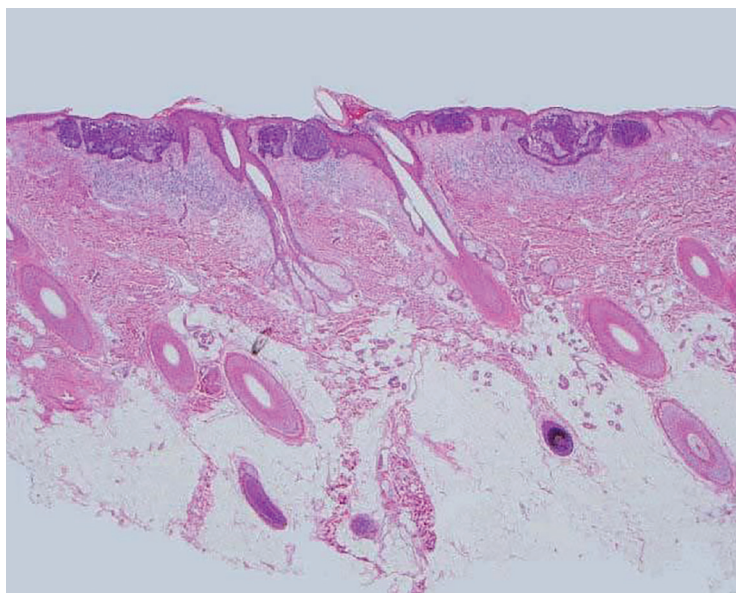
The tumor structure consists of numerous large, irregular, well-defined basal cell nodules with peripheral light-colored ranges. Basaloid tumor cells have disordered nuclei, numerous apoptotic cells, and cells at the periphery are arranged in a palisade pattern. Tumors may degenerate to form cysts.



### - Superficial type

This type consists of basaloid cell clusters that are continuous with the epidermis or hair follicles. They protrude into the dermis and are surrounded by loose mucous tissue. However, isolated clusters

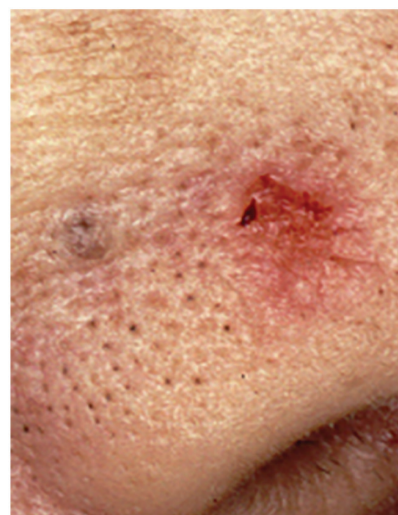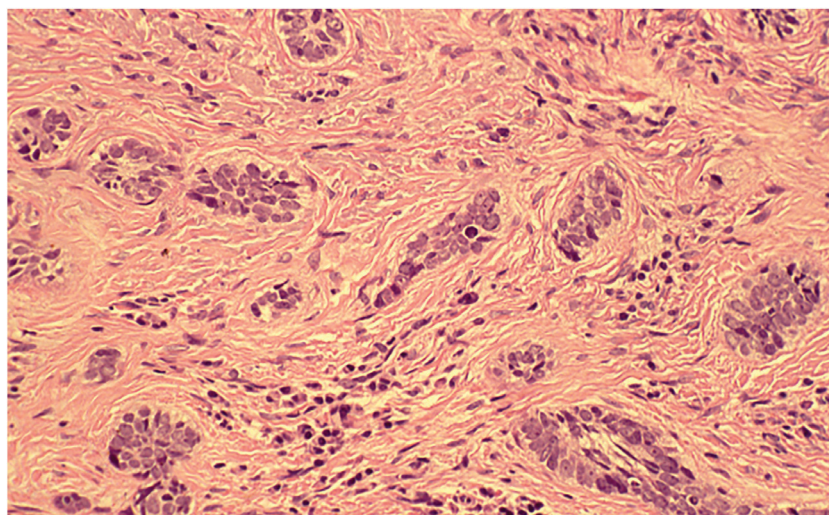
of tumor cells can sometimes be seen, indicative of the true multifocal form. In some cases, this form can be combined with other forms, such as the tumor, small tumor, and infiltrative form.



### - Micronodular type

This type consists of small diffuse foci in the epidermis that are about the same size as hair follicles. These foci may have micro-infiltrates that extend deep into the dermis and subcutaneous tissue. The tumor has a peripheral edge or is

infiltrated at irregular depths, has tentacles, and is infiltrated by discrete cells. Single nodules can be seen in the distal main tumor, making it easy to miss when evaluating the tumor margins. Perforated biopsies have a significant false-negative rate.





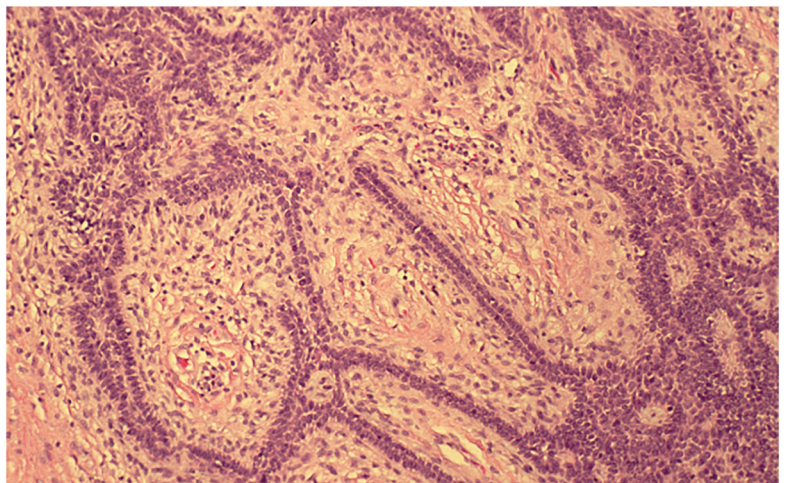
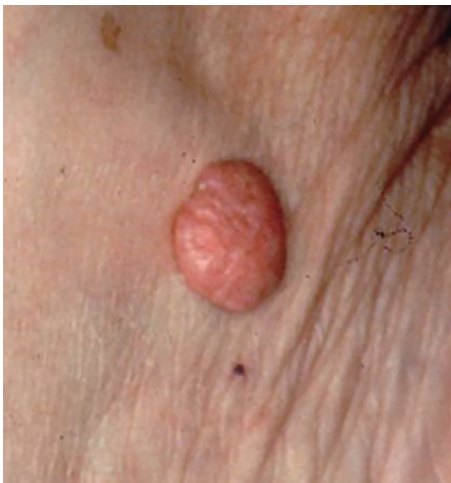### - Infiltrative type

On HE-stained slides, cancer cells are basal-colored, and basaloid cells are arranged in bands or cords with narrow cytoplasm. The tumor border is jagged and surrounded by a dense matrix of fibrous fibers, so the palisade pattern is often not seen (due to the change in the shape of the tumor). Clusters of cancer cells can vary in shape and size and may also be associated with the histopathological morphology of nodular, micronodular, and other forms. Although the tumor was deeply infiltrated or extended more

extensively below the tumor margin, there was no fibrosis and/or atrophy in the stroma, as seen in the fibrous form. This is an important sign to distinguish between infiltrative and fibrous forms. This form is commonly observed in the infiltrates around the nerve fibers.

### - Fibroepitheliomatous type

On HE-stained slides, the tumor is characterized by a network of branches and basaloid cell bands that surround the fibrous tissue, extending from the epidermis and forming a "window" image.



### - Adnexal differentiation type

Histopathological features: This type is characterized by skin appendage-like components such as ductal structures, hair follicles, and sebaceous glands. Follicular differentiation is often more pronounced than in the superficial type. Eccrine or Apocrine differentiation may also occur in this type. This is a sign that can help distinguish it from sweat gland cancer.

### - Basosquamous type

Histopathological features: The histopathology of the basosquamous carcinoma typically has 3 main parts: the expression part

of the basal cell carcinoma with dark basaloid epithelial cells, the tumor's clearly demarcated outer barrier, with pulse cracks, the possible presence of peritumor, ethmoid and glandular growth patterns in this part of the tumor. The characteristic part of squamous cell carcinoma is that the cancer cells are brighter, larger and tend to be keratinized consistent with the epidermal lesion. The intermediate part is the transitional region, in this region the cancer cells do not have the typical features of either basal cell carcinoma or squamous cell carcinoma but are intermediate in nature. Cancer cells contain more protoplasm and more intense keratinization than those of

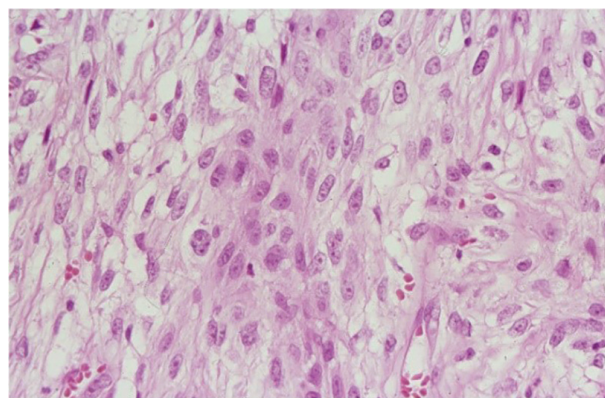
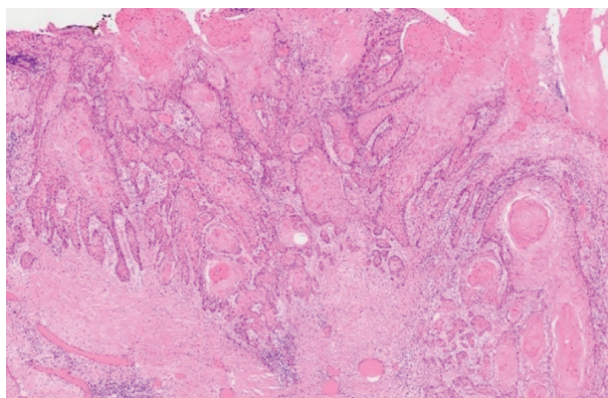
basal cell carcinoma. These tumors may fibrous centrally then spread circumferentially and invade deep into the deep dermis or subcutaneous tissue.

#### - Keratinized type

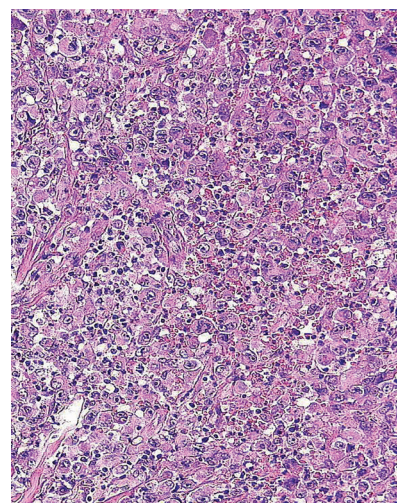
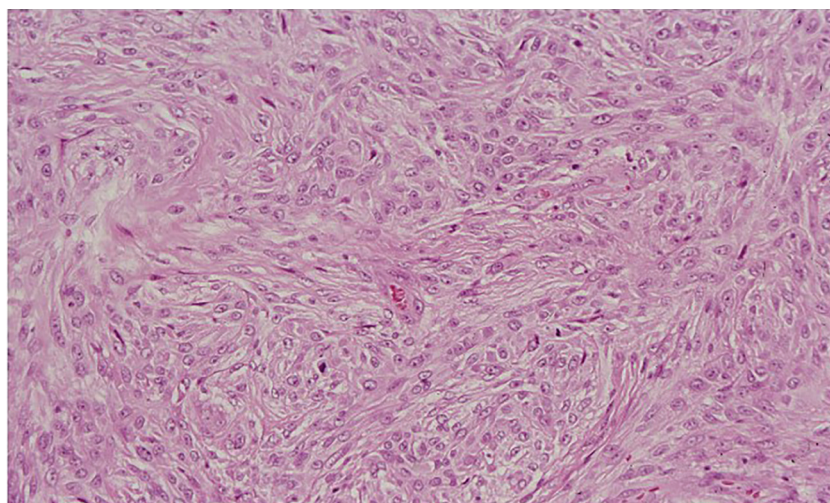
Histopathological features: The histopathology of this type has the structure of the tumor type, combined with keratinization. Keratinization can be thin, funnel-shaped or in the form of a hair follicle structure. Calcification is also common. This type characterized by small, horny cysts near the surface of the tumor must be differentiated from the basoquamous type which is often wider and has indistinct boundaries.

#### 2.1.2. Squamous cell carcinoma histopathology<sup>2</sup>

Histopathological examination by Hematoxylin-Eosin staining helps confirm the diagnosis of squamous cell carcinoma with the presence of malignant keratinocytes, several mitotic bizarre nuclei, depolarized cells, keratosis, and parakeratosis. These cells can penetrate deeply into the dermis, infiltrating nerves, blood vessels, and inflammatory cells. There may be central keratinization and the formation of horn cores. Depending on the differentiation of the cells, squamous cell carcinoma is classified as highly differentiated, moderately differentiated, and poorly differentiated.



**Highly differentiated SCC Moderately differentiated SCC**



**Poorly differentiated squamous cell carcinoma**



## 2.2. Diagnosis of cancer by immunohistochemistry<sup>3,4</sup> *Immunohistochemistry in basal cell carcinoma*

Immunohistochemistry is helpful in the differential diagnosis of similar lesions, such as benign or malignant primary skin tumors or metastasis from another organ. In fact, the images of the lesions can be very similar, sometimes making it difficult to confirm whether the patient's lesion is benign or malignant, or in which organ it is located, especially if it is at the site of interference or the tumor has invaded two or more adjacent organs.

Although immunohistochemistry has shown many benefits, there is no single immunological marker that can confirm 100% of lesions as benign or malignant. Therefore, the standard for diagnosing benign or malignant lesions has been routine hematoxylin and eosin (HE)-stained histopathology. However, in cases that are difficult to diagnose as benign or malignant, or for other purposes such as prognostication, determining treatment goals, etc., the application of immunohistochemistry is necessary based on a complete and detailed analysis of routine HE stain histopathology, associated with clinical and other laboratory information. Although the immunohistochemistry technique is performed automatically, marker specification and diagnosis still need to be done directly by the pathologist. Therefore, it is important to have a team of qualified and experienced specialists.

Basal cell carcinoma is positive for BerEP4 and Keratin markers, and most are negative for epithelial membrane antigen (EMA). In many studies, BerEP4 has been used to differentiate basal cell carcinoma (positive response) from squamous cell carcinoma (negative response).<sup>5</sup>

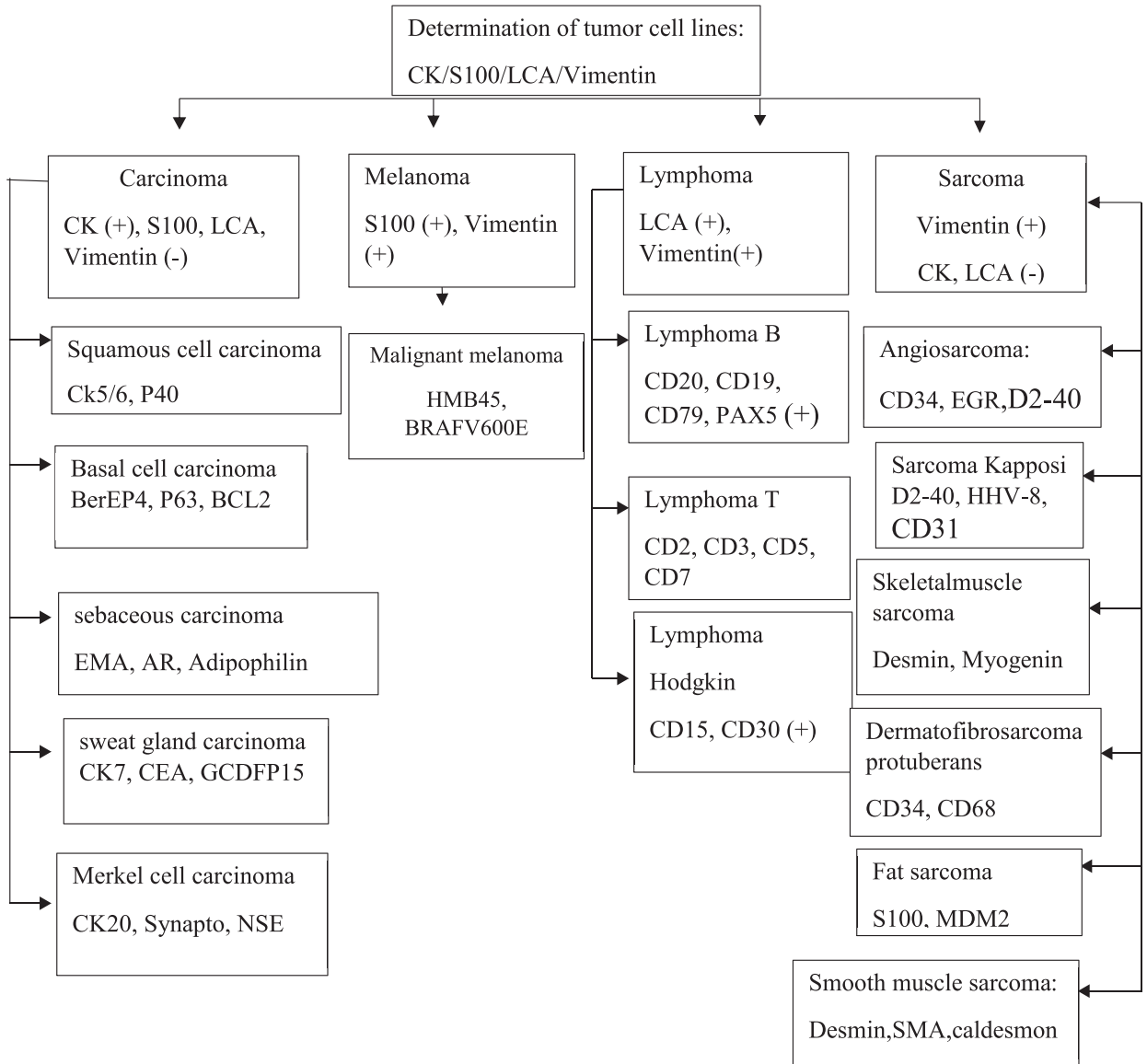
Cytokeratin 20 (CK20) is a Merkel cell marker. It is used to differentiate trichoblastoma and trichoepithelioma (positive response) from basal cell carcinoma (negative response). Androgen receptor (AR) is positive in 78% of basal cell carcinoma cases, and the simultaneous use of AR and CK20 helps differentiate desmoplastic trichoepithelioma from infiltrative basal cell carcinoma and micronodular basal cell carcinoma.

### *Immunohistochemistry in squamous cell carcinoma<sup>6,7</sup>*

Variants of squamous cell carcinoma, such as adenoid, mucin-producing acantholytic, fibrous, and spindle cell variants, are sometimes difficult to diagnose by conventional HE staining. In these cases, immunohistochemistry is helpful in detecting spiny differentiation in tumor tissue. Tumor cells are usually positive for EMA and Cytokeratin. Cytokeratin-positive squamous cell carcinoma has a much higher molecular weight than basal cell carcinoma.

Spindle cell squamous cell carcinoma is a rare type that must be distinguished from leiomyosarcoma and fibrosarcoma. The positive response to markers CK and P63 helps in the differential diagnosis in these cases.

**Diagram of basic immunological markers for the classification of malignant skin tumors**





## REFERENCES

1. Cameron MC, Lee E, Hibler BP, Barker CA, Mori S, Cordova M, Nehal KS, Rossi AM. Basal cell carcinoma: Epidemiology; pathophysiology; clinical and histological subtypes; and disease associations. *J Am Acad Dermatol*. 2019 Feb;80(2):303-317. doi:10.1016/j.jaad.2018.03.060.
2. Que SKT, Zwald FO, Schmults CD. Cutaneous squamous cell carcinoma: Incidence, risk factors, diagnosis, and staging. *J Am Acad Dermatol*. 2018 Feb;78(2):237-247. doi: 10.1016/j.jaad.2017.08.059.
3. Lin, F., & Liu, H. Immunohistochemistry in undifferentiated neoplasm/tumor of uncertain origin. *Archives of pathology & laboratory medicine*. 2014 Dec;138(12), 1583 -1610. doi: 10.5858/arpa.2014-0061-RA.
4. Compton, L. A., Murphy, G. F., & Lian, C. G. Diagnostic Immunohistochemistry in Cutaneous Neoplasia: An Update. *Dermatopathology* 2015 Apr; 2(1), 15 -42. doi: 10.1159/000377698.
5. Sunjaya AP, Sunjaya AF, Tan ST. The Use of BERP4 Immunohistochemistry Staining for Detection of Basal Cell Carcinoma. *J Skin Cancer*. 2017;2017:2692604. doi: 10.1155/2017/2692604.
6. Firnhaber JM. Basal Cell and Cutaneous Squamous Cell Carcinomas: Diagnosis and Treatment. *Am Fam Physician*. 2020 Sep 15;102(6):339-346. <https://pubmed.ncbi.nlm.nih.gov/32931212>.
7. Lobl, M., Grinnell, M., Phillips, A., Abels, J., & Wysong, A. The Correlation Between Immunohistochemistry Findings and Metastasis in Squamous Cell Carcinoma: A Review. *Dermatologic surgery*. 2021 May; 47(3), 313 -318. doi: 10.1097/DSS.0000000000002850.