



MALIGNANT SWEAT GLAND TUMOURS: A CASE SERIES

Hoang Quoc Tuan^{1,*}, Le Thi Hai Yen², Nguyen Hong Son², Nguyen Huu Sau^{1,2}

ABSTRACT

Objectives: Malignant sweat gland tumor is a very rare skin cancer with variable presentations. The objectives of this study are to examine the clinicopathological and immunohistochemical features of malignant sweat gland tumors and to discuss the treatment and follow-up for postsurgical recurrence rates.

Methods: Six patients diagnosed with sweat gland carcinoma at the National Hospital of Dermatology and Venereology between 2018 and 2023 were carefully reviewed.

Results: The cases occurred in four men and two women, ranging in age from 31 to 78 years (mean 59.3). Four of the lesions were from the scalp, one from the nose, and one from the right arm. There were three cases of Eccrine Porocarcinoma, two cases of Hidradenocarcinoma, and one case of Syringoid Eccrine Carcinoma. All of them were treated with surgery, five cases with wide local excision, and one case with Mohs micrographic surgery. Only one case had a recurrence.

Conclusions: Malignant sweat gland tumors demonstrate significant variability in clinicopathology and immunohistopathology. Surgery is the mainstay of treatment.

Keywords: *Apocrine, eccrine, malignant sweat gland tumors, hidradenocarcinoma, porocarcinoma.*

1. INTRODUCTION

Sweat gland cancer is a very rare skin cancer, accounts for only 0.05% of skin cancers overall.^{1,2} According to medical literature, the common age is the middle-aged group of 50 - 70 years.^{3,4} Common location of sweat gland cancer is in the head, face, neck.⁵ The clinical presentation of sweat

gland cancer are nothing particularly suggestive. The definitive diagnosis depends entirely on histopathology and immunohistochemistry.^{2,5} The prognosis of sweat gland carcinoma depends on many factors, which emphasize the role of histopathology.⁶ So far, there is no consensus on the treatment of various forms of sweat gland carcinoma.³ That poses significant challenges for clinicians.

We report a case series of 6 patients diagnosed with sweat gland carcinoma at the National Hospital of Dermatology within 5 years from 2018 to 2023, with different histopathological forms, treated and monitored for risk of recurrence after surgery.

¹Hanoi Medical University

²National Hospital of Dermatology and Venereology

*Correspondence: hoangquoctuanyhn@gmail.com

Received 28 June 2023

Revised 26 September 2023

Accepted 29 November 2023

DOI: <https://doi.org/10.56320/tcdlhvn.42.136>

2. MATERIALS AND METHODS

6 cases were diagnosed with sweat gland carcinoma during the period of 2018 - 2023 in the National Hospital of Dermatology and Venereology. Pertinent dermographic and clinical data were retrieved from the electronic medical records. The cases occurred in four men and two women, ranging in age from 31 to 78 years (mean 59.3). Four of the lesions were from the scalp, one from the nose and one from the right arm.

Accepted criteria on haemotoxyline and eosin sections in conjunction with immunohistochemistry were used to make the

diagnosis. Immunostaining was performing according to our laboratory's usual methods and the primary antibodies.

3. RESULTS

3.1. Clinical characteristics

6 cases were diagnosed with sweat gland carcinoma during the period of 2018-2023 in the National Hospital of Dermatology and Venereology. Pertinent dermographic and clinical data were retrieved from the electronic medical records. The cases occurred in four men and two women, ranging in age from 31 to 78 years (mean 59.3).

Table 1. Summary of patient demographics, location and morphological findings

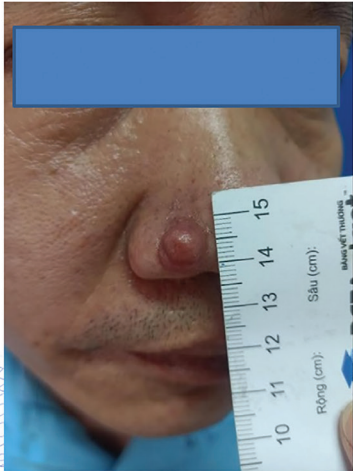Case	Sex	Age	Size	Location	Morphology	Duration	Histopathology
1	M	54	1cm	Nose	Solitary, erythematous papule, telangiectasia	8 months	Syringoid eccrine carcinoma
2	F	56	4cm	Scalp	Verrucous plaque	1 year	Hidradenocarcinoma
3	M	31	4cm	Scalp	Keratotic plaque	12 years	Hidradenocarcinoma
4	M	78	20cm	Scalp	Glant verrucous plaque, ulcerated, bleeding	15 years	Eccrine porocarcinoma
5	F	74	3cm	Scalp	Verrucous plaque, ulcerated, crusted, bleeding	8 years	Eccrine porocarcinoma
6	M	63	1cm	Right Arm	Verrucous, hyperpigmented	1.5 years	Eccrine porocarcinoma

Of the 6 patients, there were 4 men, 2 women. The median age of 6 patients was 59.3, of which 5/6 patients were over 50 years old. The location of the tumor in 4/6 patients located on the scalp, one from the nose and one from the right arm. In terms of disease duration, the majority of cases with lesions lasted for many years. The size of the lesions were variable, ranging from 1cm to 20cm.

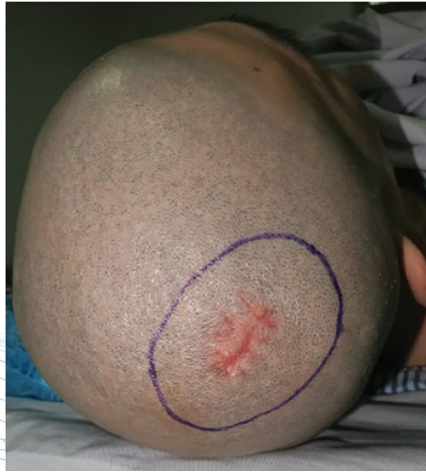All lesions were solitary, but could be a papule or a plaque. Features of lesions with ulceration, verrucous were seen in 4/6 patients. Bleeding and telangiectasia were seen. In summary, clinical features of lesions in all 6 patients were directed to skin cancer, but there were no distinctive signs directed to sweat gland carcinoma.



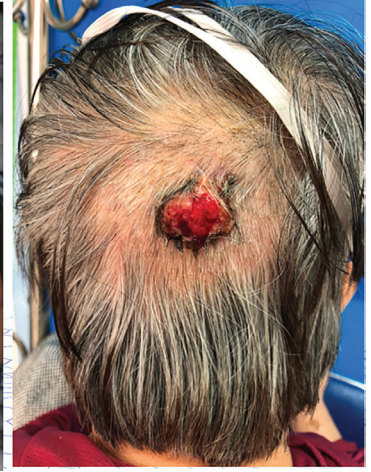Case 1



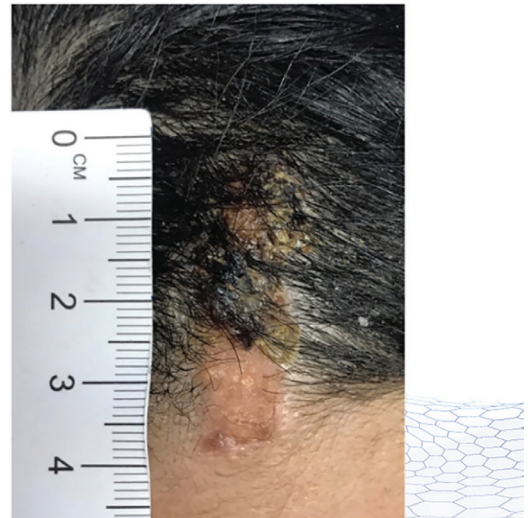
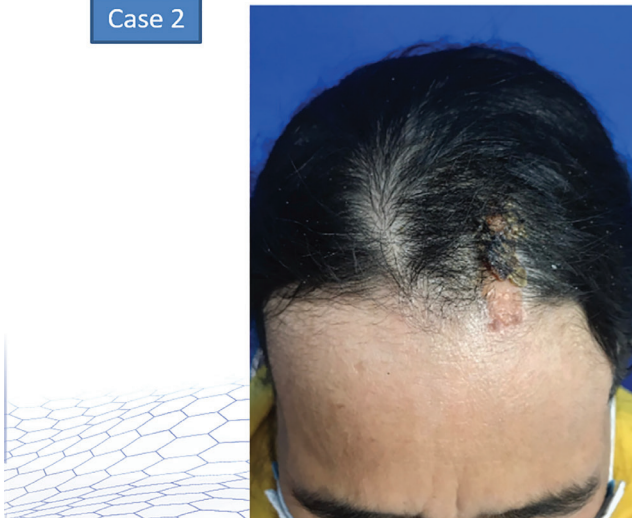Case 3



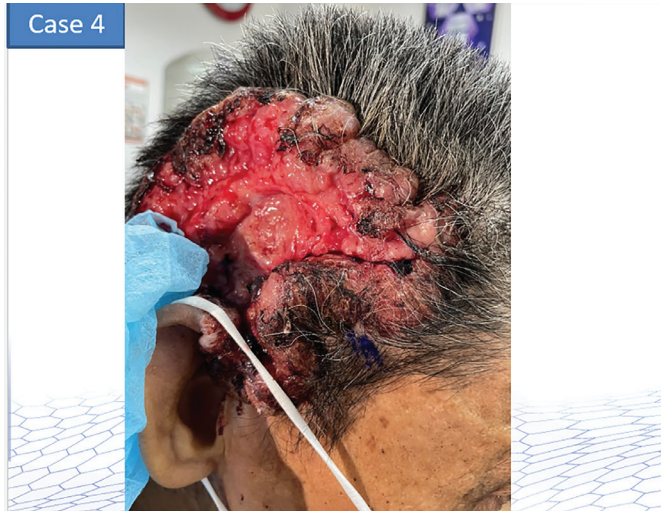Case 5



Case 2



Case 4



Case 6

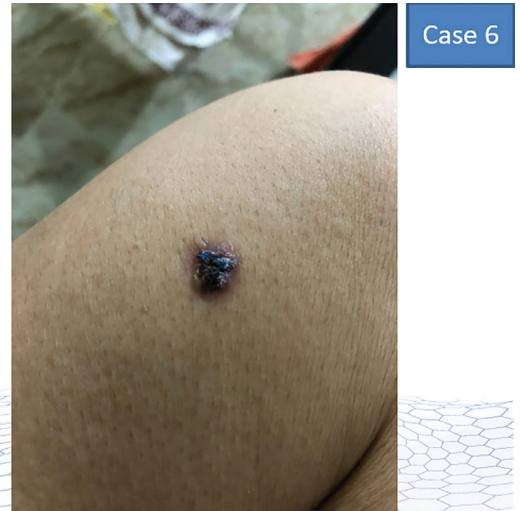

Figure 1-3: Clinical images of 6 cases

3.2. Histopathology

All 6 patients underwent a biopsy of the lesion as HE stained histopathology to confirm the diagnosis. 3 patients were diagnosed with Eccrine porocarcinoma, 2 patients were diagnosed with Hidradenocarcinoma, and 1 patient was diagnosed with Syringoid eccrine carcinoma.

Table 2. Summary of histopathological features of 6 cases

Case	Infiltrate growth pattern	Deep extension (Breslow)	Perineural invasion	Lymphovascular invasion	Ulcerated, necrosis	Cyto - nuclear atypia	Mitoses	Histopathology
1	+	+	-	-	-	Minimal	Rare	Syringoid eccrine carcinoma (SEC)
2	+	+	-	-	+	Significant	Abundant	Hidradenocarcinoma
3	+	+	-	-	-	Moderate	Abundant	Hidradenocarcinoma
4	+	+	-	-	+	Significant	Abundant	Eccrine porocarcinoma
5	+	+	-	-	+	Significant	Abundant	Eccrine porocarcinoma
6	+	+	-	-	-	Significant	Abundant	Eccrine porocarcinoma

All 6 cases had same histopathological features of tumour is infiltrate growth pattern and deep extension. 3/6 cases had ulcerated and necrosis. 4/6 cases had significant cyto-nuclear atypia. High mitotic rate was seen in 5/6 cases. Perineural invasion and lymphovascular invasion were not seen in any case.

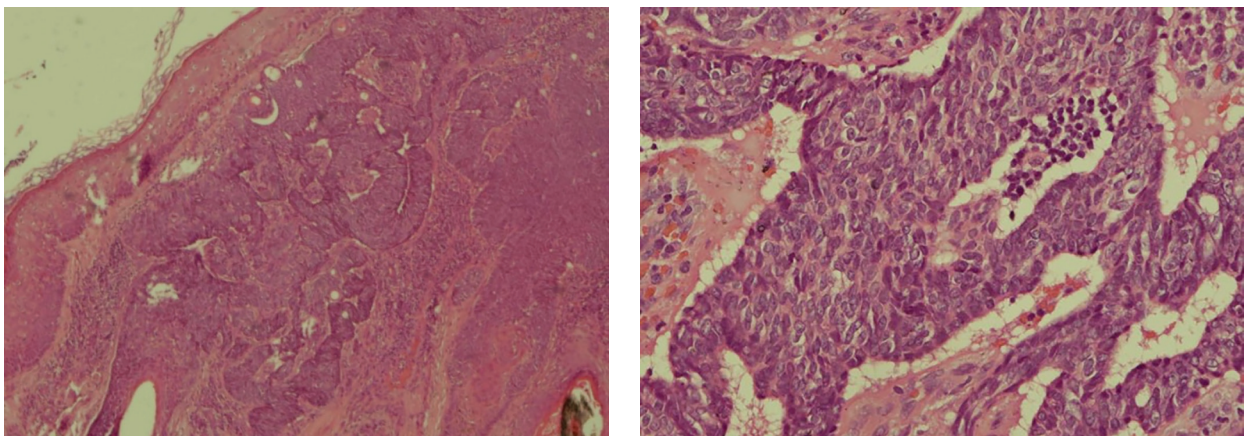


Figure 4-5. Representative HE slides of case 2: Hidradenocarcinoma

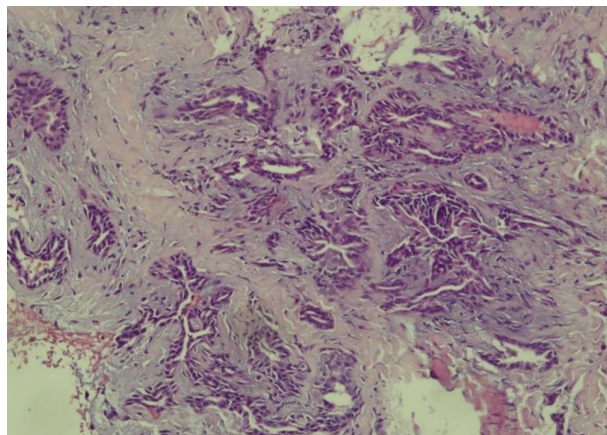
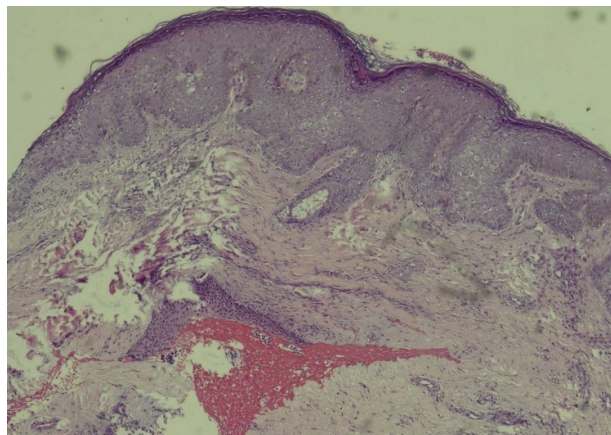


Figure 6-7. Representative HE slides of case 1: Syringoid eccrine carcinoma

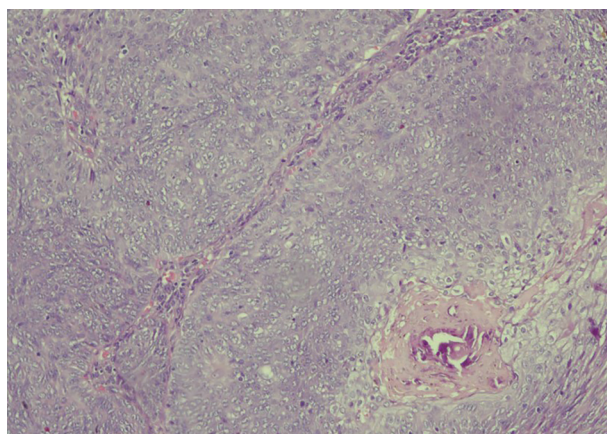
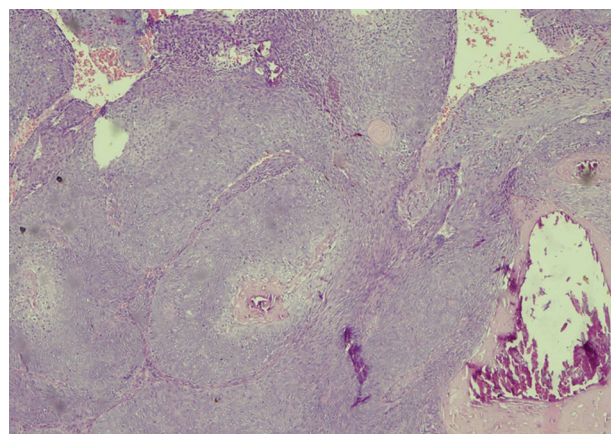


Figure 8-9. Representative HE slides of case 6: Eccrine porocarcinoma

3.3. Immunohistochemistry

Patients who were diagnosed sweat gland carcinoma with HE histopathology then underwent immunohistochemistry with appropriate markers. Immunostaining was performed according to our laboratory's usual methods and the primary antibodies which were available.

Immunostaining was variable among all 6 cases. Ki67 was expressed in four of six cases while Cytokeratin (CK) was expressed in three of six cases. CK7 and EMA was expressed in two of six cases. GCDFP-15 and BerEp4 were not expressed in any case.

Table 3. Summary of the immunohistochemistry features of 6 cases

Case	CK	CK7	CEA	Ki67	CK20	BerEp4	GCDFP-15	EMA	Histopathology
1		+		+ focal	-		-		Syringoid eccrine carcinoma (SEC)
2	+			+		-	-		Hidradenocarcinoma
3	+			+		-	-		Hidradenocarcinoma
4	+	+		+		-		+	Eccrine porocarcinoma
5									Eccrine porocarcinoma (not done IHC)
6		-	-					+	Eccrine porocarcinoma

3.4. Treatment and follow-up

All patients diagnosed with variable subtype of sweat gland carcinoma by histopathology and immunohistochemistry were assessed the risk of local invasion and metastasis. 5/6 patients were identified with carcinoma in situ, only 1 case of sweat gland carcinoma with lymph node metastases was patient No. 4 with stage III. In terms of treatment, all patients were undergone surgery, namely wide surgical excision for

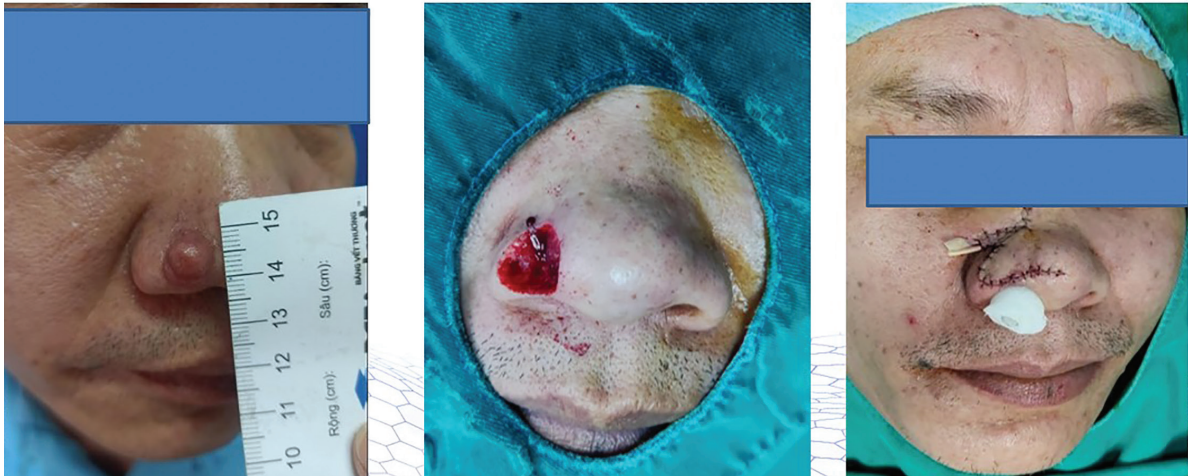
Hidradenocarcinoma and Eccrine porocarcinoma (3cm margin at least) and Mohs surgery for Syringoid eccrine carcinoma. Patient No. 4 was accompanied by lymphadenectomy and adjuvant treatment after surgery with radiation therapy. All patients after surgery were monitored for follow-up examination to assess the risk of recurrence, the results so far are quite good, except patient No.4 had recurrent.

Table 4. Summary of lymph node metastasis, stage, treatment and follow-up of 6 cases

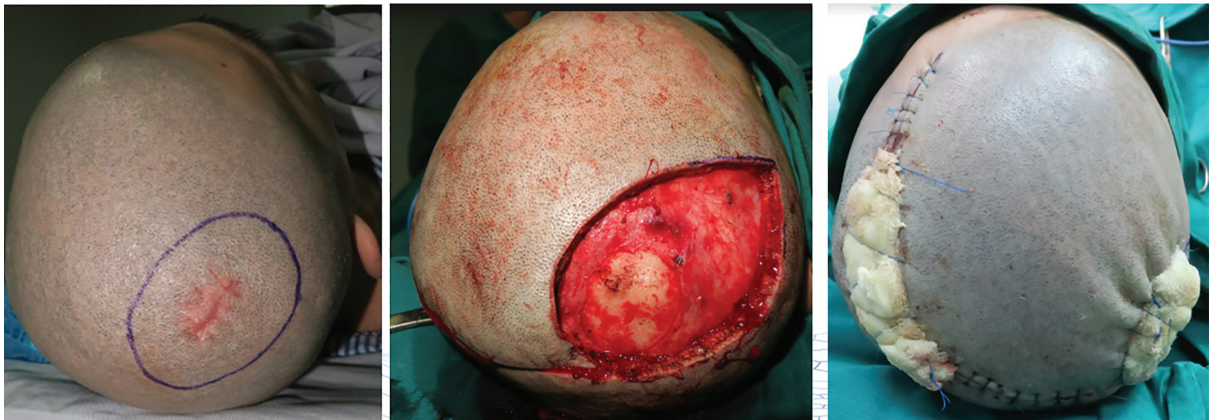Case	Histopathology	Lymph node biopsy	Lymph node metastasis	Distant metastasis	Stage	Treatment	Follow up
1	Syringoid eccrine carcinoma	-	-	-	I	Mohs surgery	No recurrent
2	Hidradenocarcinoma	+	-	-	I	Wide Surgical excision	No recurrent
3	Hidradenocarcinoma	+	-	-	I	Wide Surgical excision	No recurrent
4	Eccrine porocarcinoma	+	+	-	III	Wide Surgical excision + Lymphadenectomy + Radiation	Recurrent
5	Eccrine porocarcinoma	+	-	-	I	Wide Surgical excision	No recurrent
6	Eccrine porocarcinoma	+	-	-	I	Wide Surgical excision	No recurrent



Case 1



Case 3



Case 5

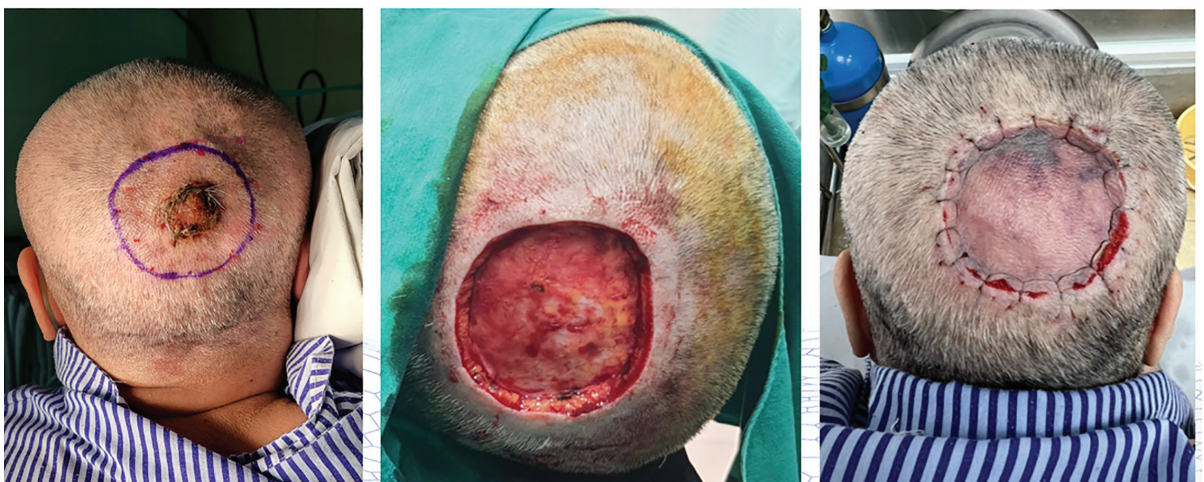


Figure 10-12: Images of lesion, defect and reconstruction of case 1,3,5, respectively

4. DISCUSSION

Sweat gland cancer is a very rare skin cancer, accounts for only 0.05% of skin cancers overall.^{1,4} According to medical literature, the common age is the middle-aged group of 50 - 70 years. In our hospital, only 6 cases were diagnosed with sweat gland carcinoma within 5 years (2018 - 2023). And most of the cases presented in the 5th - 7th decades of life. The clinical appearance of sweat gland carcinoma is nothing particularly suggestive. Common location of sweat gland carcinoma is on the head and face. The lesion is usually solitary, hard, firm, 1 - 10cm in size, accompanied by ulceration and verrucous. Rapid or slow clinical progression is highly dependent on histopathology. Most of our cases presented for several years and slow evolution.⁵

We emphasize the importance of histopathology in the diagnosis of sweat gland cancer, such as ³ ductal, mucinous, microcystic adnexal, and adenocystic carcinoma. From understanding the anatomy of the sweat glands, it is possible to determine that the cancer comes from the sweat glands and other skin structures. On histopathology, we will determine which type of sweat gland cancer, eccrine or apocrine, and determine whether the cancer originated in the secretory part or in the duct section. From there, a histopathological diagnosis of sweat gland cancer is made. We have to notice several clinicopathological features that are associated with a poor prognosis including ulceration, necrosis, deep invasion (greater than 7mm), lymphovascular invasion, high mitotic rate, infiltrate growth pattern, perineural invasion, nuclear pleomorphism.

Regarding immunohistochemistry, it must be emphasized that immunohistochemistry does not distinguish whether sweat gland cancer is eccrine or apocrine.⁷ Its important role is the differential diagnostic value of sweat gland cancer from other types of skin cancer such as basal cell carcinoma (BCC), squamous cell carcinoma (SCC), melanoma, sebaceous carcinoma or Paget's disease. Always remember that no single marker is completely specific to a tumor. Both histopathological features and immunohistochemical staining results with multiple markers are necessary for a definitive diagnosis of sweat gland cancer.

In terms of treatment, to date there is no consensus guideline on sweat gland cancer.³ Most authors agree that surgery is the mainstay treatment in the early stages.⁸ For hidradenocarcinoma, the authors recommend wide surgical excision with or without lymph node dissection as the first choice.⁶ This is a very aggressive malignant cancer with a 5-year survival rate of less than 30%. The post-operative recurrence rate for hidradenocarcinoma is 10 - 30%.⁷ So early diagnosis is critical to treatment outcome and quality of life for patients. Some post-operative adjuvant therapies such as chemotherapy, radiotherapy or targeted therapy are concerned. For Porocarcinoma, the prognosis is similar to Hidradenocarcinoma.⁷ For the Syringoid eccrine carcinoma, this is a well- differentiated carcinoma, usually only locally invasive with a better prognosis. Mohs micrographic surgery is highly recommended.⁷ After surgery, patients should be regularly and closely kept in follow-up.

The table below summarizes the prognosis and recommendations for follow-up for sweat gland cancers.



Table 5. Prognostic groups of sweat gland carcinoma⁶

S. No.	Prognosis	Risk of local recurrence	Risk of distant metastasis	Example	Surgical margin	Clinical follow up
1	Good	Low	Low	Trichiemmal carcinoma	1 cm	Every six months
2	Intermediate	High	Low	Microcystic adnexal carcinoma Adenoid cystic carcinoma Mucinous carcinoma	2-3 cm (5cm for microcystic adnexal carcinoma)	Every three months
3	Poor	High	High	Porocarcinoma Hidradenocarcinoma Apocrine carcinoma Sebaceous carcinoma Pilomatrix carcinoma	At least 3 cm	Every month

5. CONCLUSION

Sweat gland cancer is a very rare skin cancer that accounts for only 0.05% of overall skin cancers. The clinical appearance of sweat gland cancers is nothing particularly suggestive. Definitive diagnosis completely depends on histopathology and immunohistochemistry. The prognosis of sweat gland carcinoma depends on many factors, which emphasize the role of

histopathology. So far, there is no consensus on the treatment of various forms of sweat gland cancer. Surgery remains the mainstay. Lymph node dissection or post-operative adjuvant treatments depends on the stage of the disease as well as the histopathology. Further studies including larger numbers of patient with sweat gland cancer should be performed to establish the optimal approach to diagnosis and treatment.

REFERENCES

1. Seger, E. W., Neill, B. C., & Tolkachjov, S. N. Adnexal and Sebaceous Carcinomas. *Dermatologic clinics*. 2023 Jan;41(1), 117 -132. doi:10.1016/j.det.2022.07.010.
2. Obaidat NA, Alsaad KO, Ghazarian D. Skin adnexal neoplasms--part 2: an approach to tumours of cutaneous sweat glands. *J Clin Pathol*. 2007 Feb;60(2):145-59. doi: 10.1136/jcp.2006.041608.
3. Yugueros P, Kane WJ, Goellner JR. Sweat gland carcinoma: a clinicopathologic analysis of an expanded series in a single institution. *Plast Reconstr Surg*. 1998 Sep;102(3):705-10. doi: 10.1097/00006534-199809030-00014.
4. Ahn CS, Sangüeza OP. Malignant Sweat Gland Tumors. *Hematol Oncol Clin North Am*. 2019 Feb;33(1):53-71. doi: 10.1016/j.hoc.2018.09.002.
5. Cardoso JC, Calonje E. Malignant sweat gland tumours: an update. *Histopathology*. 2015 Nov;67(5):589-606. doi: 10.1111/his.12767.
6. Soni A, Bansal N, Kaushal V, Chauhan AK. Current management approach to hidradenocarcinoma: a comprehensive review of the literature. *Ecancermedicalscience*. 2015 Mar 19;9:517. doi: 10.3332/ecancer.2015.517.
7. Goyal A, Marghitu T, Goyal N, Rubin N, Patel K, Goyal K, O'Leary D, Bohjanen K, Maher I. Surgical management and lymph-node biopsy of rare malignant cutaneous adnexal carcinomas: a population-based analysis of 7591 patients. *Arch Dermatol Res*. 2021 Oct;313(8):623-632. doi: 10.1007/s00403-020-02143-5.